




File No.: 039355

Nationality: Q

### GYNAECOLOGICAL SHEET

DR LEILA HAMID MEDICAL CENTER   
 File No: 039355  
 Name: MAHA AHMED ALJAEEL  
 QID No: 29763402247 Sex: Female  
 Mob: 55601929 ADDRESS: UM SALAL

Age: 27 Yrs  
 Marital Status: 2 1/2 yrs.  
 and's Name: Faisal Ahmed Aljael  
 Phone: Residence Phone:

#### SYMPTOMS:

Came to check vulval skin tags.  
 - no abnormal vag discharge.  
 - not lactating & not on Contraception

Medical History: diabetic on insulin P.H. C/S only. F.H. M.C.D.M) F.C.H.T.N)

#### MENSTRUAL HISTORY:

Menarche: 10 - 11 Yrs L.N.M.P 6.8.2024  
 Menstrual Habits: regular last for 6 days every month.  
 Menstrual Symptoms: none Menopause:  
 Parity: P 1 Abortion 1 Ectopic LCB 1 1/2 Yr.  
 ♀ 1 ♂ 1 - EANCIS due to Failure to progress.

#### EXAMINATION

General Examination: Ht. 160 cm Wt. 59.6 Kg BMI Kg/m<sup>2</sup> Bp 100/70 mm Hg  
 cooperative, not pale.

Chest, C.V.S.

Abdomen: NAD.

Breasts: not examined

PELVIC EXAMINATION: there is wart's like lesion in mons pubis  
 Speculum Exam. and inner thigh to rough surface - no  
 Bimanual Exam. abnormal vag. discharge.  
 Rectal Exam. not done -

#### Investigation Requested:

lesions were removed under local anaesthesia  
 and electrocauterized, specimen sent for histopathology

Diagnosis:

A wart's like lesions in genital area. for investigation.

Plan of Management: Pt reassured. given for pap smear + viral typing [HPV] next week because she is still menstruating

Next Appointment:

Name : Maha Ahmed AL-Jael  
Lab. No. : 332445511  
Contract. : Dr. Layla Bashir  
Patient No. : 29763402247  
File No. :

Sample Date : 18/08/2024 19:15 PM  
Report Date : 26/08/2024 14:45 PM

Branch : Qatar Waab      Age : 27 Year      Sex : Female      this sample was collected outside lab

**Human Papilloma Virus (HPV28) detection and genotyping by PCR**      **Molecular Biology Unit**

Test	Result	Ref. Range
HPV Sample Type	Cervical Brush on SurePath	
Sample Type		
HPV Type 16:	Not Detected	Not Detected
HPV Type 18:	Not Detected	Not Detected
Other High Risk HPV		
HPV Type 26:	Not Detected	Not detected
HPV Type 31:	Not Detected	Not Detected
HPV Type 33:	Not Detected	Not Detected
HPV Type 35:	Not Detected	Not Detected
HPV Type 39:	Not Detected	Not Detected
HPV Type 45:	Not Detected	Not Detected
HPV Type 51:	Not Detected	Not Detected
HPV Type 52:	Not Detected	Not Detected
HPV Type 53:	Not Detected	Not Detected
HPV Type 56:	Not Detected	Not Detected
HPV Type 58:	Not Detected	Not detected
HPV Type 59:	Not Detected	Not Detected
HPV Type 66:	Not Detected	Not Detected
HPV Type 68:	Not Detected	Not Detected
HPV Type 69:	Not Detected	Not Detected
HPV Type 73:	Not Detected	Not detected
HPV Type 82:	Not Detected	Not detected
Low Risk HPV		
HPV Type 6:	Not Detected	Not detected
HPV Type 11:	Not Detected	Not detected
HPV Type 40:	Not Detected	Not Detected
HPV Type 42:	Not Detected	Not Detected
HPV Type 43:	Not Detected	Not Detected
HPV Type 44:	Not Detected	Not Detected
HPV Type 54:	Not Detected	Not Detected
HPV Type 61:	Not Detected	Not Detected

Name : Maha Ahmed AL-Jael  
Lab. No. : 332445511  
Contract. : Dr. Layla Bashir  
Patient No. : 29763402247  
File No. : this sample was collected outside lab

Branch : Qatar Waab      Age : 27 Year      Sex : Female

**Molecular Biology Unit**

**Human Papilloma Virus (HPV28) detection and genotyping by PCR**

Test	Result	Ref. Range
HPV Type 70:	Not Detected	Not Detected

**Comments**

Persistent infection with human papillomavirus (HPV) is the main cause of cervical cancer and its precursor cervical intraepithelial neoplasia (CIN) [Burd, Eileen M. 2003]. There are more than 118 different types of HPV [Bernard HU. 2005], and approximately 40 different HPVs that can infect the human anogenital mucosa [de Villiers EM, etal 2004]. However, only a subset of 13 to 19 of these types is considered high-risk for the development of cervical cancer [Clifford GM etal 2003]. Although persistent infection with high-risk (HR) HPV is a necessary cause of cervical cancer, more than 90% of infected women will mount an effective immune response and clear the infection within 6 to 24 months without any long term health consequences [Moscicki, A. etal 2006].

**Methodology Brief:-**

The HPV28 Assay is a qualitative multiplex real-time PCR for simultaneous amplification and detection of target nucleic acids of 19 high-risk HPV types (16, 18, 26, 31, 33, 35, 39, 45, 51, 52, 53, 56, 58, 59, 66, 68, 69, 73, 82) and 9 low-risk HPV types (6, 11, 40, 42, 43, 44, 54, 61, 70) as well as Internal Control (IC). in patient specimens. This test was developed, and its performance characteristics have been determined by Al Borg Medical laboratories – Jeddah –Saudi Arabia. It has not been cleared or approved by the FDA. Al Borg Medical Laboratories are regulated under CLIA guidelines (CAP# 7197774) as qualified to perform high complexity testing. This test is used for clinical purposes. It should not be regarded as investigational or for research.

**Limitation:-**

- 1-Detection of high, low-risk HPV is dependent on the number of copies present in the specimen and may be affected by specimen collection methods, cellularity, patient factors, stage of infection and the presence of interfering substances.
- 2- Though rare, mutations within the highly conserved regions of the genomic DNA of Human papillomavirus covered by the Test's primers and/or probes may result in failure to detect the presence of the viral DNA.
- 3-This test types is not recommended for evaluation of suspected sexual abuse.
- 4- performance of the HPV28 Test has not been adequately established for HPV vaccinated individuals.
- 5-A negative high-risk HPV result does not exclude the possibility of future cytologic HSIL or underlying CIN2-3 or cancer, a regular follow up and liquid Pap testing are recommended.

Reviewed By:

  
**Dr. Hisham El-Banawy**  
Anatomical & Clinical Pathology  
License No. 3482

Dr. Hisham El-banawy  
Consultant

Verified By : Heba Elmasry  
Printed By: System  
All Rights Reseved © National Technology

Name : Maha Ahmed AL-Jael  
Lab. No. : 332445511  
Contract. : Dr. Layla Bashir  
Patient No. : 29763402247  
File No. :

Sample Date : 18/08/2024 19:15 PM  
Report Date : 19/08/2024 13:12 PM

Branch : Qatar Waab Age : 27 Year Sex : Female Int. No. : 4G24.3463  
Cytology Unit

this sample was collected outside lab

### Liquid Based Pap (Sure Path®)

#### SPECIMEN TYPE

Pap smear cytology (sure path)

#### CLINICAL DATA

Genital warts

#### ADEQUACY

Adequate, endocervical cells

#### INTERPRETATION

Smear shows superficial and intermediate squamous cells.  
Mild mixed inflammatory cells infiltration.  
Degenerative and regenerative changes seen.  
There are no features of intraepithelial lesion or viral change.

#### RESULT

Negative for intraepithelial lesion or malignancy (NILM).  
Reactive cellular changes associated with inflammation.  
Inflammatory / Mild to moderate cervicitis / Clinical correlation.

#### RECOMMENDATION

Follow up according to HPV result.

#### COMMENT

- HPV-DNA testing is advised and can be performed on the provided Liquid PAP sample upon request. (Within 30 Days)
- Review of previous biopsy with Accession No 332444141 is done showing Excision biopsy (Mons pubis at the right groin): Picture favors Condyloma accuminatum.
- This report follows the updated Bethesda System for Reporting Cervical Cytology, third edition, 2014.

Name : Maha Ahmed AL-Jael  
Lab. No. : 332445511  
Contract. : Dr. Layla Bashir  
Patient No. : 29763402247  
File No. :

Sample Date : 18/08/2024 19:15 PM  
Report Date : 19/08/2024 13:12 PM

this sample was collected outside lab

Branch : Qatar Waab Age : 27 Year Sex : Female Int. No. : 4G24.3463  
Cytology Unit

## Liquid Based Pap (Sure Path®)

### EDUCATIONAL NOTES

- Pap test is a screening test for cervical cancer with inherent false negative result.
- Combined HPV DNA testing with cytological examination (Pap smear) is proved to be more sensitive and improves the specificity in detecting cervical abnormalities and minimizes the need of invasive diagnostic procedures when compared to Pap test alone.
- The Interim guidance was developed by American Society for Colposcopy and Cervical Pathology (ASCCP) and the Society for gynecological oncology (SGO) with input from representatives of five other organizations including the American Cancer Society (ACS), American College of Obstetricians and Gynecologists (ACOG), American Society for Clinical Pathology (ASCP), American Society of Cytopathology (ASC) and the college of American Pathologists (CAP).

#### References:

- 2012 Updated Consensus Guidelines for the Management of Abnormal Cervical Cancer Screening Tests and Cancer Precursors; American Society for Colposcopy and Cervical Pathology (ASCCP) Consensus Guidelines Conference.
- Huh WK et al 2015. Use of primary high-risk human papillomavirus testing for cervical cancer screening: interim clinical guidance.
- 2016 Practice Bulletin No. 168; American College of Obstetricians and Gynecologists (ACOG).

Verified By :

Dr. Elif Hasan



Name : Maha Ahmed AL-Jael  
Lab. No. : 332444141  
Contract. : Dr. Layla Bashir  
Patient No. : 29763402247  
File No. : 039 355

Sample Date : 11/08/2024 14:31 PM  
Report Date : 14/08/2024 15:21 PM

Branch : Qatar Waab Age : 27 Year

this sample was collected outside lab

Sex : Female Int. No. : 4S24.4747  
Pathology Unit

**Biopsy (Small)**

**SPECIMEN:**

Excision biopsy (Mons pubis at the right groin)

**CLINICAL DATA:**

Warty lesion over mons pubis and right groin.

**MACROSCOPY:**

Received in a labelled container with patient identification and fixed in formalin, were multiple fragmented, firm, gray brown tissues measured 1.0 cm in aggregates. Entire specimen submitted in one cassette.

Cold Ischemia Time: Not written

Fixation Time: 24 hours

Prepared by : Dr. Delaram

Assisted by : Joane

**MICROSCOPY:**

Polypoid pieces of tissue were seen showing hyperkeratosis, parakeratosis, acanthosis, and papillomatosis with foci of basophilic cytoplasmic inclusion and koilocytic changes. No malignancy.

**DIAGNOSIS:**

Excision biopsy (Mons pubis at the right groin):

Picture favors Condyloma acuminatum.

**COMMENT:**

- Clinical correlation please.
- Ki67 can be done to support the diagnosis.
- Follow up with PAP smear and HPV.

Name : Maha Ahmed AL-Jael  
Lab. No. : 332444141  
Contract. : Dr. Layla Bashir  
Patient No. : 29763402247  
File No. :

Sample Date : 11/08/2024 14:31 PM  
Report Date : 14/08/2024 15:21 PM

this sample was collected outside lab

Branch : Qatar Waab Age : 27 Year Sex : Female Int. No. : 4S24.4747  
Pathology Unit

### Biopsy (Small)

Verified By :

Jr. Delaram Mohammad  
Mahmoud Arwlan

FRCPATH, License No. 2778

Dr. Delaram M. Mahmoud  
Histopathology & Cytology  
License No. 2778  
Al Borg Laboratory

PATIENT	: FAISAL AHMAD ALJAAL	FILE NO	: 44235
AGE	: 31y 11m 12d	INVOICE NO	: 97797
GENDER	: Male	NATIONALITY	: Yemen
TELEPHONE	: 66944419	INVOICE DATE	: 11/08/2024
REF. DOCTOR	: DR.MAHMOUD SALAMA		
INSURANCE	:		

URINE ANALYSIS

TESTS	RESULT	REFERENCE VALUE
-------	--------	-----------------

URINE PHYSICAL EXAMINATION :

Color	Yellow	Yellow
Aspect	Clear	Clear
S. Gravity	1015	1.005 - 1.028
pH	6.5	5 - 8
Leucocytic estrase	Absent	Absent
Nitrite	Absent	Absent
Protien	Absent	Absent
Glucose	Absent	Absent
Ketone	Absent	Absent
Urobilinogen	Normal Trace	Absent
Bilirubin	Absent	Trace
Blood/Hb.	Absent	Absent

URINE MICROSCOPIC EXAMINATIO

W.B.Cs / HPF	0-2	0 - 7
R.B.Cs / HPF	2-4	0 - 6
Epith. Cells / HPF	Absent	Few to some
Casts	Absent	Absent
Crystals	Absent	Absent
Amour. Elements	Absent	Absent
Comment		Absent



PATIENT :	FAISAL AHMAD ALJAAL	FILE NO :	44235
AGE :	31y 11m 12d	INVOICE NO :	97797
GENDER :	Male	NATIONALITY :	Yemen
TELEPHONE :	66944419	INVOICE DATE :	11/08/2024
REF. DOCTOR :	DR.MAHMOUD SALAMA		
INSURANCE :			

**URINE CULTURE & SENSITIVITY**

TESTS	RESULT	REFERENCE VALUE
-------	--------	-----------------

**Urine Examination, C/S**

Specimen:

Urine

Isolated Organism (s):

No growth after 48 incubation at 37c.



### PAP Smear REQUEST

Patient Name: Maha Ahmed Patient QID: \_\_\_\_\_ Patient File No: 039353  
 Nationality: P Age: 27 Gender  M  F Date of Request: 18-8-24  
 Tel/Mobile No.: 55601929 E-mail: \_\_\_\_\_  
 Patient Clinical Data: genital wart's Married?  YES  NO Children No: 1

for pap smear for histopathology + HPV high & low risks.

#### Sample obtained by:

- Ayres Spatula  Brush  Liquid-based Cytology

#### Smear Site:

- Cervix  Endocervix  Endometrial Aspiration  Labia  
 Vaginal Vault  Vaginal Wall  Vulva

#### Menstrual State:

- Post Menopausal  Post Partum  Pregnant

- HPV Vaccination?  YES  NO

LMP: 6 Day 8 Month 2024 Year

#### Current Hormone Use:

- On Hormone?  YES  NO  
 For Contraception  YES  NO  
 For Therapy  YES  NO  
 Estrogen & Progesterone  YES  NO  Estrogen Only  Progesterone Only  
 Other Medication (Specify): \_\_\_\_\_

#### Other relevant information:

- Abnormal Bleeding  YES  NO  
 Suspicious Lesion  YES  NO  
 Using IUD  YES  NO

#### Previous Uterine Procedures: None

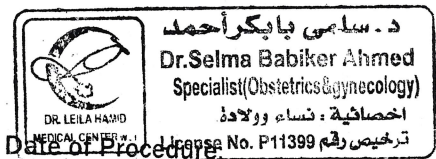- Bite Biopsy  Cryotherapy  Endometrial Biopsy  Loop  
 Colposcopy  Electrocautery  Cone Biopsy  Laser

#### Hysterectomy:

- Subtotal (uterus removed, cervix remain)  Total (uterus & cervix excised)  
 Date conducted: \_\_\_\_\_ Day \_\_\_\_\_ Month \_\_\_\_\_ Year  
 Prior Malignancy  YES  NO

Requesting Physician Signature & Stamp: \_\_\_\_\_

Procedure Done By (Name & Signature): \_\_\_\_\_



Madinat Khalifa South  
 Tel.: +974 4486 8675  
 Fax: +974 4487 6227



Our Location

مدينة خليفة الجنوبية  
 هاتف: +974 4486 8675  
 الفاكس: +974 4487 6227

Al Waab St. - Al Aziziya  
 Tel.: +974 4450 0074  
 Fax: +974 4460 3040



Our Location

شارع الوعب - العزيزية  
 هاتف: +974 4450 0074  
 الفاكس: +974 4460 3040



"e-Jaza" – "Sick Leave" "إجازة مرضية" – "إجازة"

Dr. LEILA H MEDICAL CENTER

Ref No. / Order Id : 20443936

Date : Aug 11, 2024

Patient Details

بيانات المريض

QID / Passport No.

29763402247

رقم البطاقة الشخصية جواز السفر

Name

MAHA AHMED AM ALJAE

الإسم

Place of Work

HMC

مكان العمل

Primary Diagnosis :

POST VULVAL WARTS LIKE LESION CRYO CAUTRIZATION

التشخيص المبدئي:

Unfit For (1) day(s)

From 11/08/2024 to 11/08/2024

غير لائق لمدة (1) يوم أيام

من 11/08/2024 إلى 11/08/2024

Practitioner Details

بيانات الممارس

Name

Selma Babiker Ahmed

الإسم

Licence No.

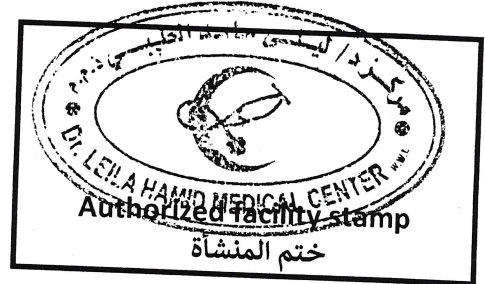
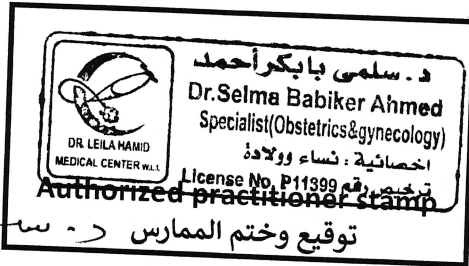
P11399

رقم الترخيص الطبي

Scope of Practice

Obstetrics & Gynecology

نطاق العمل



Notes

- Certificate is valid only if it is signed and stamped by the concerned healthcare practitioner and facility
- Certificate is invalid if any corrections are made, Please scan QR Code for checking details.
- Certificate is issued at patient's request.
- Certificate must be submitted to patient's organization within 7 days.
- Document number (QID/Passport no.) should correspond to the patient
- Residents and nationals should provide a QID no. otherwise sick leave is invalid.



Date 11 / 8 / 2024

**New Patient Registration Form**

Full Name ..... الإسم الكامل صالح محمد علي الجول

Date of Birth ..... تاريخ الميلاد 1/6/1997

Marital Status  Single / أعزب  Married / متزوج  Divorced / مطلق  Widowed / أرمل

Gender:  Male / ذكر  Female / أنثى Nationality ..... الجنسية سعودية

Occupation ..... المهنة عمدة داخل

I.D Number ..... رقم البطاقة الشخصية 29763402247

Telephone No. (Home) ..... رقم الهاتف المنزلي

Mobile Number ..... رقم الجوال 55601929

Emergency Contact Person ..... أقرب الأقراب

Emergency Contact Number ..... رقم هاتف

Address: Building No.  Zone No.  Street No.  العنوان:  
رقم البناية رقم المنطقة رقم الشارع

How did you hear about our Center من أين سمعت عن مركزنا؟  
 Advertisements / إعلانات  Referral by doctor  Friends & Relatives / أصدقاء وأقارب  
 Others / أخرى

How do you want us to address you ? كيف تفضل أن نناديك ؟  
 By Name / بالإسم  By No / بالرقم  Others (please specify) / حدد الطريقة التي تفضلها

I receive my Rights & Responsibilities إستلمت قائمة حقوق و مسؤوليات المريض

Signature ..... التوقيع [Handwritten Signature]

File Number 039355



## نموذج الموافقة المستنيرة

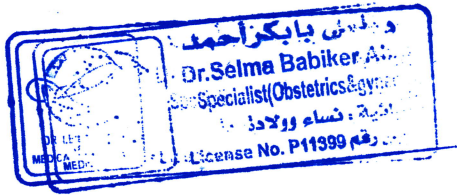### موافقة على العلاج الطبي

أوافق و أوجه الطبيب / الطبيبة المعالج لي لمقابلتي وأجراء الكشف علي والقيام بتشخيصي ومعالجتي بالأدوية أو العقاقير أو عمليات إن إحتاج الأمر ، وأنا أدرك أن من مسؤوليتي الحضور في الوقت المحدد لمواعيدي واتباع أوامر الطبيب المعالج لي كما أدرك بأنني لدي الحق في طلب رأي ثاني لو لم أكن راضيا / راضية عن الرعاية المقدمة لي.

وأوافق على أي اجراء فحص طبي إن طلب مني من أجل تقديم رعاية طبية صحيحة.

وقد قرأت ووافقت على نموذج الموافقة المستنيرة حسب تعليمات وزارة الصحة العامة.

اسم المريض / المريضة: صالحه الجبل



التاريخ: 11/8/2024

ملف رقم: 039355

التوقيع: [Signature]

State of Qatar  
ID. Card



دولة قطر  
بطاقة إثبات شخصية



ID. No: 29763402247 الرقم:

D.O.B. 01/06/1997 تاريخ الميلاد:

Nationality: QATAR / قطريه الجنسية:

Date of expiry: 09/06/2031 الصلاحية:



Name: MAHA AHMED A M ALJAEI

الإسم: مها احمد علي محمد الجعل

منطقة 56 - شارع 867 - مبنى 18

Serial No: 4364501330242475

العنوان:

الرقم المسلسل:

مدير إدارة الجنسية و وثائق السفر  
Authority's signature

توقيع حامل البطاقة  
Holder's signature

