

Dr. Leila Hamid
Medical Center



مركز
د. ليلى حامد - للطبي

معيبر الشمالي - شارع السلام بناية رقم ٨٠ شارع ٩٩٠ المنطقة ٥٣ هاتف: ٤٤٨١٧٦٥٢ - ٤٤٨١٧٦٥١ - فاكس: ٤٤٨١٧٩٩٦
Al Salam Street - North Muaitheer Building No. 80, Street 990, Zone 53,
Tel.: 44817651 - 44817652 Fax: 44812796 Mobile: 55868523 - 55341474 - E-mail: dr.leilamedcenter@gmail.com

OBSTETRIC RECORD

File No.: 033336

NAME: Amel Ahmed Subahn Nationality: SUD
AGE: 21 PROFESSION: VISIT VISA
HUSBAND'S NAME: Mohamed Abdulghani Sediq
ADDRESS: Bin Mahmud TEL: 50687888
DATE OF MARRIAGE: 1 yr.
BLOOD GROUP: A R.h.: rrc
L.N.M.P.: 2.1.2022 E.D.D.: 9.10.2022

PAST MEDICAL HISTORY

HYPERTENSION: FH DIABETES: FH
ASTHMA: / TOXOPLASMOSIS: /
DRUG ALLERGIES: /
OTHERS: H1N1 twice ovarian cysts

OBSTETRIC HISTORY

G I P 0 ABORT. 0 ECT.

Years	PREGN.	LABOUR	OUTCOME
	Primi		

Report
Endomet for
viable fetal pole
6-wks, yolk
8/10/22
1-u embryo
GA 6wks EPD
d collection of
CRL 2.6cm
regular well
ac or blood
used scan next
3am & 4am
4 uv: seen N
2
+ Wk = LFD
placenta post
Retr. placental
can N-T. 1.1mm
2/10/22

- first marriage for both.
- staying together 2 + 3/12
- dialy SR.
- No Contraception



File No.: 033336

Nationality: SUD

not

GYNAECOLOGICAL SHEET

DR. LEILA HAMID MED. CENTER

File No: 033336



NAME: AMEL AHMED MOHAMMED SUBAHI

ID NO: VISIT VISA

MOB: 50687888

SEX: FEMALE

ADDRESS: BIN MAHMOUD

Age: 21 yrs

Marital Status: 1 yr

band's Name: Mohammed Abdulghani Seddig

Mobile Phone:

Residence Phone: - 28 yrs healthy - non smoker

SYMPTOMS:

Mid cycle pain till flow of next period subside 2 days after, diagnosed as Luteal phase insufficiency on duphaston take. Take clomid this month, No C.T.

Medical History:

NAD

P.H. NAD

F.H. HTN - DM

MENSTRUAL HISTORY:

History of ovarian cyst twice.

Menarche:

L.N.M.P

14-11-21

Menstrual Habits:

Regular 13 yrs Lasts for 5 days

Menstrual Symptoms:

Spasmodic

Menopause:

Parity: P

Abortion 0

Ectopic

LCB



EXAMINATION

General Examination: Ht. 164 cm Wt. 69.2 Kg BMI Kg/m² Bp 120/70 mm Hg

Normal female look, GBC - husband

Chest, C.V.S.

Normal.

Abdomen:

Normal, tender Lt iliac fossa rebound -

Breasts:

No galactorrhoea

PELVIC EXAMINATION:

Speculum Exam.

cx of nulli, tender Lt adnexa ex utero

Bimanual Exam.

free Rt adnexa -

Rectal Exam.

Investigation Requested:

AVF - uterine regular contour & endometrium 8 mm

Rt ov. small & of normal echo

Lt ov. - cyst bilocular one locule 33mm Ø 2nd small 2cm

Diagnosis:

? twisted Lt ov. - cyst

Plan of Management:

for O12

Next Appointment:

Name : Amel Ahmed Mohammed

File Number : 033336

Date	Cycle Day	Drugs	Endo.	Right Ovary	Left Ovary
22-12-2021 68.3 110/70 T-36°C	11-12-2021 5pm D11	—	GA 13.8mm FFCDS	NIS good reserve No mature follicle	one cyst 3cm, ovary above 4 in front part.
11-01-22 69.2 120/80	02-1-22 ^{pm} D 9.	-	GA 9.6mm	No leading small only FFCDS +	old follicle 12mm or ?? cyst remnant

Notes:



MEDICAL REFERRAL LETTER Gynae and General Patients

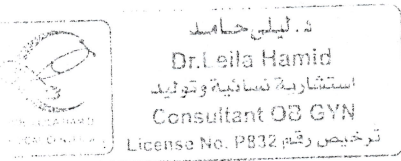


To Doctor: Alwakia hospital
From : Dr. Leila Hamid Medical Center
Patient's Name : Amel Ahmed Mohammed
Age : 21 yrs Nationality : SUD
is P Abortion Ectopic

- Low Risk * Telvic pain for 4/12
 High Risk starts 70 of period
 I N F Continues till onset of period
 Others e dyspareunia

Referred :

- For Booking to OPD
 To E R



Referred By:

Doctor's Name :

[Signature]

Date : 07 DEC 2021

Abd today tender Lt IF
rebound -ve rigidity -w.
PV tender Lt adnexa, excite +ve
Uls - small Lt ov. cyst bilobular, one
locule 3cm & 2nd 2cm.
No FFCDs
? Twisted Lt ov. cyst
NB used Clomid by her own this
month only



مركز د. ليلي حامد الطبي

DR. LEILA HAMID MEDICAL CENTER

شهادة طبية

Medical Certificate

Name: Amel Ahamed Subahi : الإسم
Age: 21 yrs : العمر
Nationality: SUD : الجنسية
Med. No: 033336 : الرقم الطبي
Date: 2/3/2022 : التاريخ
Diagnosis: 1 trimester abortion 9 wks : التشخيص

السيدة أمل حامل بطفل التوكل في اسبوع التاسع تفاد
منه تترك دموي تخرج منه انفصال جزئي عن الرحم
كما يوجد نزول الجبين مع تترك دموي خارج بقدر صغره أيضا

Treatment: Duphastm + cydogest + sedentan : العلاج
life + Regular
full her medical problem resolves weekly
(Certificate to whom it may concerns)

Fit for work: : صالح للعمل
Unfit for work: : غير صالح للعمل
Days: : أيام

Stamp

Doctor's Signature

Amel

ID: 145 28-04-22 12:47

GLU NEGATIVE
BIL NEGATIVE
KET NEGATIVE
SG <=1.005
BLO NEGATIVE
PH 6.0
PRO NEGATIVE
URO 0.2 E.U./dL
NIT NEGATIVE
LEU NEGATIVE

LEU NEGATIVE

DR. LEILA H. MEDICAL CENTER W.L.L.

Tel. 44817651/ 44817652 - Fax: 44812796

Al Salam Street - North Muaither

Villa No.: 80 & 82



مركز د. ليلي حامد الطبي ذ.م.م.

تليفون: ٤٤٨١٧٦٥١ / ٤٤٨١٧٦٥٢ - فاكس: ٤٤٨١٢٧٩٦

شارع السلام - معيذر الشمالي

فيلا رقم: ٨٠ و ٨٢

وصفة طبية Prescription

No

Date: 28.4.22 التاريخ:

Patient's name: Amel Ahmed اسم المريض:

File No.: 03336 رقم الملف:

Age: 21 yr. ANIC, 17+ العمر:

Rx

Century 21 Ca & vit D tabs
6 bottles

سبوتون ٢١ كالسيوم وفيتامين د
٦ زجاجات

Feroglobin caps

سبوتون فريوجلوبين
٢٠ زجاجات

Doctor's signature: [Signature]

Email: dr.leilamedcenter@gmail.com

Mobile: 55868523

DR. LEILA H. MEDICAL CENTER LLC

Tel. 44817651/ 44817652 - Fax: 44812796
Al Salam Street - North Muaither
Villa No.: 80 & 82



مركز د. ليلى حامد الطبي ذ.م.م.

تليفون: ٤٤٨١٧٦٥١ / ٤٤٨١٧٦٥٢ - فاكس: ٤٤٨١٢٧٩٦
شارع السلام - معيذر الشمالي
فيلا رقم: ٨٠ و ٨٢

وصفة طبية Prescription

No

Date: 5.4.22 التاريخ:

Patient's name: Amel Ahmed اسم المريض:

File No.: 033336 رقم الملف:

Age: 24yrs 24yrs Dr. Leila H. Medical Center العمر:

Rx

- Triderm Lintel cream

- Cxartin

- Senso derm gel

استخدام كريمين واليوجا حسب الحوص

- Clartine tab.

بمعدل ١٠٠٠ في اليوم حسب الحوص

Doctor's signature:

Email: dr.leilamedcenter@gmail.com
Mobile: 55868523

Email: dr.leilamedcenter@gmail.com
Mobile: 55868523